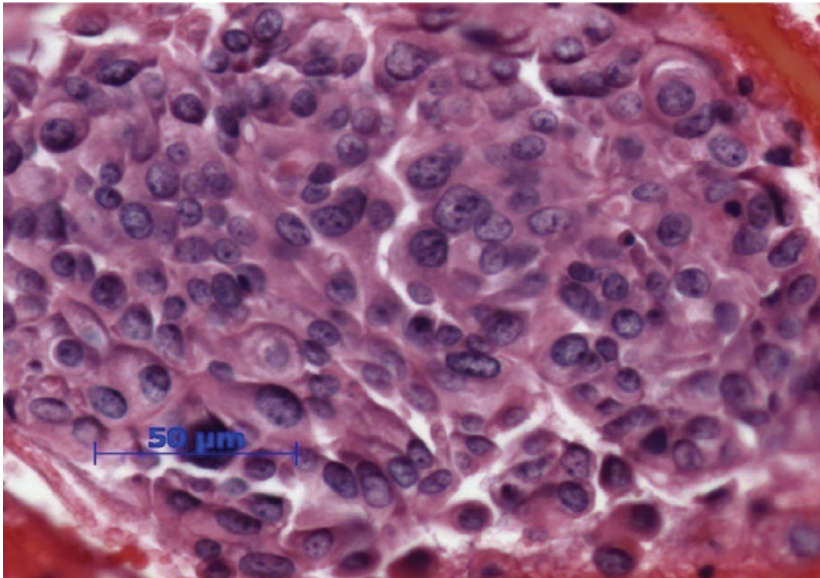


## FNA of Supraclavicular Mass



### Patient Case 1:

A 76 year old woman complaining of chest pain and shortness of breath is referred after a chest x-ray shows a pulmonary nodule. CT scan reveals suspicious lesions in the liver and lung, retroperitoneal adenopathy, and a thickening in the cecum. Pancreas is clear; breast exam and mammography negative; endoscopy and colonoscopy negative. Fine needle aspirate is done on a supraclavicular lymph node.

### Pathologist's Impression:

Poorly differentiated carcinoma; possible primaries include breast, lung, pancreas, stomach, salivary gland, and ovary.

### Follow-up Testing:

Repeated breast exam and mammogram; both negative. PET scan showed diffuse activity in lymph nodes, lung, left iliac region, and left breast. MRI and ultrasound of breast negative.

### Oncologist's Impression:

Breast or gastric. Treatment started: Gemzar and Xeloda; radiation to left hip.

### Work Up:

#### Serum Tumor Markers

Serum CA 19.9	14,000
Serum CA 27 - 29	165
CEA	12.4

#### IHC Stains

CK7	Positive
CK20	Negative
CK 5/6	Focal Positive
CK Cocktail	Positive
TTF-1	Negative
ER	Negative
PR	Negative
HER2	3+ Positive
P63	30% Positive
Melan-A	Negative
CDX2	Negative
S100	Negative

## Tissue of Origin<sup>®</sup> Test Ordered.

### Pathologist Interpretation and Tissue of Origin Results:

The Tissue of Origin<sup>®</sup> test suggests a BLADDER ORIGIN in this case with MODERATELY HIGH CONFIDENCE. The Tissue of Origin<sup>®</sup> test has effectively ruled out a derivation from the 8 tissue types with scores ranging from 0.6 to 3.1. Kidney, Colorectal, and Ovarian, with Similarity Scores of 16.9, 13.8 and 11.7, are also unlikely to be the origin, but have not been explicitly ruled out.

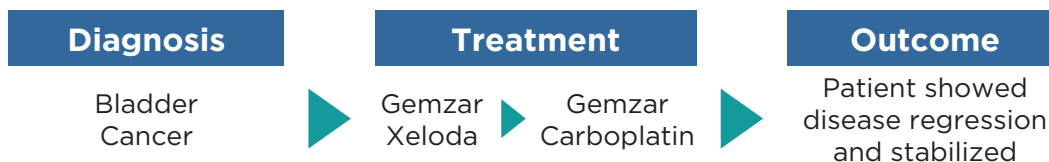
Tissue	Similarity Score	Low 0-5	High 100
Bladder	23.4		◆
Kidney	16.9		◆
Colorectal	13.8		◆
Ovarian	11.7		◆
Breast	6.8	◆	
Non-Small Cell Lung	6.8	◆	
Pancreas	6.4	◆	
Gastric	3.1	◆	
Sarcoma	2.9	◆	
Non-Hodgkin's Lymphoma	2.1	◆	
Hepatocellular	1.9	◆	
Thyroid	1.8	◆	
Prostate	1.2	◆	
Melanoma	0.7	◆	
Testicular Germ Cell	0.6	◆	

### Post Tissue of Origin<sup>®</sup>:

Based on the Tissue of Origin<sup>®</sup> results, a cystoscopy was done and was negative. Urine cytology was atypical but not diagnostic. Washings from the renal pelvis were performed and were positive for malignant cells, leading to a diagnosis of primary urothelial carcinoma.

### Therapy:

The patient had a good response to 8 cycles of carboplatin and Gemzar; CT showed regression of all disease and her CA 19.9 dropped to <200. Several months later, the disease started slowly progressing, and the patient received 6 cycles of cisplatin and Taxol and had a partial response, but after 3 months the disease slowly progressed again. The patient is currently on cisplatin/Gemzar and after 19 months, she is alive and doing well.



*“The Tissue of Origin<sup>®</sup> test effectively eliminated the possibilities of breast, pancreas, or lung cancer. Knowing the patient’s primary cancer allowed me to change therapy. The patient has responded well, and has a good quality of life.”*

- Dr. Mark Yoffe, Raleigh, NC